



Original Article



Treatment of Avian Trichomoniasis by Tannin-based Herbal mixture (*Artemisia Annua*, *Quercus infectoria*, and *Allium Sativum*)

Soheil Sadr¹ , Seyed Ali Ghafouri^{1,*} , Abolfazl Ghaniei¹ , Danial Jami Moharreri¹ , Marzieh Zeinali¹ , Nasim Qaemifar¹ , Parian Poorjafari Jafroodi² , Zahra Hajiannezhad³ , and Amir Hossein Atazade¹

¹Department of Clinical Sciences, Faculty of Veterinary Medicine, Ferdowsi University of Mashhad, Mashhad, Iran

²Department of Chemistry, Faculty of Science, The University of Guilan, Rasht, Iran

³Department of Pathobiology, Faculty of Veterinary Medicine, Ferdowsi University of Mashhad, Mashhad, Iran

* **Corresponding author:** Seyed Ali Ghafouri, Department of Clinical Sciences, Faculty of Veterinary Medicine, Ferdowsi University of Mashhad, Mashhad, Iran.
Email: saghafouri@um.ac.ir

ARTICLE INFO

Article History:

Received: 11/09/2022

Accepted: 27/10/2022

Keywords:

Control

Herb

Pigeon

Tannin

Trichomonas gallinae

ABSTRACT

Introduction: *Trichomonas gallinae* (*T. gallinae*) infects numerous species of birds worldwide. Many antiprotozoal drugs have been utilized for therapeutic purposes. Herbal plants extracts do not result in drug resistance or tissue residue; therefore, they are a dependable and safe substitute for treating trichomoniasis. The current study, the antitrichomonal properties of three herbal plants (*Quercus infectoria*, *Artemisia annua*, and *Allium sativum*) were compared to those of metronidazole in pigeons.

Materials and methods: In this experiment, 32 pigeons were used, each of which was divided into four groups with four replicates. All groups were experimentally infected with *T. gallinae* except for group D. Group A was treated with a herbal mixture (80% *Quercus infectoria* extract, 11% *Artemisia annua* extract, and 9% *Allium sativum* extract [standardized to 8% total tannic acid]; Coccyphyt-L®; Makian Dam Pars Science-Based Company), while Group B was given metronidazole. The positive control group C was experimentally infected but not treated with *T. gallinae*, while group D remained healthy throughout the experiment. The experiment consisted of a performance index, weight gain, wet mount, and biochemical and hematological examination.

Results: Compared to metronidazole, the treatment with a herbal mixture significantly reduced the pathogenic effects of *Trichomonas* spp. After a week of treatment, chickens in group A were nearly healthy and, in some respects, superior to those in the metronidazole treatment group.

Conclusion: In conclusion, the antiprotozoal properties of the aforementioned herbal mixture suggest its use as an alternative antitrichomonal agent to chemotherapeutic drugs in trichomoniasis treatment.

1. Introduction

Avian protozoal trichomoniasis is a harmful infection caused by the *Trichomonas gallinae* (*T. gallinae*) protozoan parasite^{1,2}. This infection is widespread among wild and domestic birds, especially those of Columbiformes, such as pigeons and doves^{3,4}. The parasite is transmitted from infected mothers to their offspring via crop milk feeding in doves and pigeons⁵. Transmission among adults occurs through contaminated food, and water³. Lesions caused by *T. gallinae* can be categorized as mild, moderate

subclinical infections, and severe irritation infections of the upper gastrointestinal tract with lesions in the pharynx that can cause death by starvation due to the obstruction of the esophageal lumen^{6,7}. However, chronic disease can also affect the liver. Pigeons afflicted with canker are treated with various medications⁸. For several years, nitroimidazoles, including metronidazole (MTZ), have been the drugs of choice for treating trichomoniasis in birds⁹. However, due to their potential carcinogenicity, their use in

food-producing animals is prohibited¹⁰. Another issue associated with MTZ use is drug resistance¹¹. Consequently, a scientific effort is required to develop novel and improved treatment options, especially to manage the priority of resistant strains¹². Herbal compounds appear to be a viable treatment for avian trichomoniasis, among other parasitic infections¹³. Herbal mixtures are possible alternatives for the control of avian trichomoniasis¹⁴. Some compound sources with antiprotozoal and antimicrobial activities, such as Phytogetic feed additives (known as probiotics and botanicals), essential oils, and herbal extracts, are highly effective for this purpose^{15,16}. Antioxygenic, insecticidal, anti-mycotic, antiparasitic, and antiviral effects have been demonstrated by herbal components^{17,18}. Due to their anti-oxidation, antibacterial, hypocholesterolemic properties, feed supplementation with herbal extracts has recently been enhanced^{19,20}. The medicinal effects of *Quercus infectoria* (*Q. infectoria*) include anti-inflammatory, astringent, antidiabetic, antimicrobial, and gastroprotective properties^{21,22}. *Quercus infectoria*, which contains gallotannins, gallic acid, tannins, and other compounds, controls eimeriosis in birds, including oocyst production, lesion score reduction, and mortality²³. Tannins are a group of polyphenolic substances that are primarily found in plant areas and exhibit a variety of biological activities, including antiparasitic, antimicrobial, antiviral, anti-inflammatory, antioxidant, and immunomodulation^{24,25}. Tannins are a naturally occurring heterogeneous group of phenolic compounds with diverse structures that can bind to and precipitate proteins²⁶. Extract of *Q. infectoria* is a potent antimicrobial compound for decontaminating eggshells and analyzing its probable antimicrobial activity^{27,28}. *Artemisia* herb contains bioactive compounds and rich nutrients, the majority of which can be used therapeutically; thus, its extract or leaf powder can also be used as a natural herbal medicine feed additive²⁹. Additionally, the diverse biological effects of *Artemisia annua* (*A. annua*), which has antimalarial properties, have been investigated. *Artemisia annua*³⁰ contains artemisinin as one of its primary constituents. This substance is also toxic to protozoan parasites, including *Toxoplasma gondii*, *Theileria equi*, *Neospora caninum*, and *Leishmania donovani*³¹⁻³⁴. Additionally, *A. annua* aids in fever treatment and immune regulation. In addition, it has analgesic, antibacterial, anti-inflammatory, anti-schistosomiasis, antiviral, and anticancer effects^{35,36}. This substance generated oxidative stress and induced reactive oxygen species (ROS) by degrading the iron-implanted peroxide complex³⁷. In addition, *A. annua* contains numerous phytochemicals, flavonoids, and phenolic substances, which may aid birds in absorbing large quantities of N2 and sustaining commensal microflora³⁸. *Allium sativum* has been used as a seasoning and traditional medicine for decades³⁹. It has antifungal, antibacterial, antiparasitic, antiviral, antioxidant, anti-thrombotic, anti-cancerous, anticholesteremic, and vasodilator effects included⁴⁰. *Allium sativum*, often used in alternative medicine, has attracted immense interest in the medical literature⁴¹.

Allium sativum, which is frequently utilised in alternative medicine, has generated a great deal of interest in medical literature⁴¹. *Allium sativum* has the highest sulphur content, including allicin and other biological activities⁴². Other non-sulfur components, such as, saponins, proteins, and phenolic compounds, can also help with its antiparasitic effects of Thiosulfate allicin⁴³. As part of our ongoing efforts to examine herbal substances for potential biological activity, the current study is a comparative version designed to evaluate the antitrichomonal efficacy of a natural formulation. This formulation contains extracts of *Q. infectoria*, *A. Annua*, and *A. Sativum*.

2. Materials and Methods

2.1. Ethical approval

All applicable international, national, and/or institutional guidelines for the care and use of animals were followed.

2.2. Birds and housing

Thirty-two pigeons of the same age were purchased from the local incubation facility. The birds were relocated to the Veterinary Medicine Department of the Ferdowsi University of Mashhad (FUM), Mashhad, Iran. As part of the growing process, the pigeons were placed on a slatted floor in specially designed just for growing birds. In this experiment, birds were provided with as much food and water as they required, and no chemical drugs were used. They were fed a typical commercial diet and isolated into four groups of eight. The birds fed and grew stronger in the first 7 days in preparation for infection by *T. gallinae*. The clinical examination of the birds for infection with this protozoan and the wet slide test were negative. The birds were given minerals and vitamins for seven days to ensure their health.

2.3. Parasites

Parasites were cultivated *in vitro* dipping swabs in test tubes containing glucose-serum broth medium (GSB) with pH 7. The tubes were incubated at 37°C for seven days. Using a hemocytometer, the results of the culture were tallied. *T. gallinae* isolates were not exposed to antibiotics to preserve their pathogenicity and prevent a decrease in their hemolytic activity. Isolates were subcultured every 48 hours when parasites in the logarithmic growth phase exhibited more than 95% activity and regular morphology. On day 7, around 12000 trophozoites feed each bird through a stomach tube to challenge the birds.

2.4. Registration of clinical signs

During the experiment, all groups of birds were evaluated daily for clinical symptoms, and the signs were recorded. Each disease symptom represents one point. A bird with all four marks receives a score of 4, while a bird

with no marks receives a score of 0. Symptoms include fatigue, incapacity to fly, incapacity to drink and eat, and offensive odor and oral fluid.

2.5. Treatment and grouping

All groups, with the exception of group D, were experimentally infected with *T. gallinae*. On day 12 (five days after infection), when the birds exhibited characteristic disease symptoms, treatment was initiated. Group A received a herbal mixture (Cocci Phyt®) [80% *Quercus infectoria* extract, 11% *Artemisia annua* extract, and 9% *Allium sativum* extract (standardized to 8% total tannic acid); Makian Dam Pars Science-Based Company] at a dose of 5 drops orally for seven days. In contrast, Group B was administered 50 mg/kg of metronidazole for seven days. Group C did not receive any medication, making it the control group. Group D served as the negative control because it was not infected and was maintained in good health throughout the experiment.

2.6. Weighing

The process of weighing was repeated three times for each group, and the average weight of each group was computed. The first weighing process was performed on day 7 (before making birds infected), the second was five days after infections (on day 12), and the last was after full treatments on day 17.

2.7. Wet mount sample

To confirm the diagnosis of trichomoniasis wet-mount preparations of specimens were scanned for *T. gallinae*. At the end of the treatment, wet-mount slides were used to evaluate the treatments. Permanent slides stained with Giemsa were examined with an oil immersion lens.

2.8. Hematological and biochemical parameters

In three phases, two blood samples were taken from four squabs of each group. The first was conducted on the first day of arrival, the second was seven days after infection, at the peak of sickness, and the last was after full treatments. On heparin, the first sample was collected for hematological analysis, including total and differential leukocyte counts, erythrocytic, and hemoglobin. In addition to estimating the total proteins, albumin, globulin, aspartate aminotransferase (AST), and alanine aminotransferase (ALT) the serum is separated from the blood to determine the concentrations of albumin, globulin, aspartate aminotransferase (AST (ALT).

2.9. Data analysis

ANOVA and post hoc tests were applied to the body weight, ALT, total leukocyte, and eosinophil count data. R artificial intelligence software, version 4.2.1, was utilized for all data analysis. The discrepancy was deemed

statistically significant when the p-value was less than 0.05 for all the data analysed.

3. Results

3.1. Parasitology

Based on the morphology, the trophozoites were determined to be pear-shaped and flagellated. *Trichomonas gallinae* Trophozoites are found in the mouth and gastrointestinal tract.

3.2. Weekly weight gains

Table 1 shows the average weight of the birds in each group after 17 days of the experiment. The most significant weight gains were observed in group D, which did not undergo *Trichomonas* trophozoites. Throughout the test, they consistently had the highest average weight Group C gained the least amount of weight because they were not given any medications during the study. After treatment, groups A and B demonstrated excellent performance and comparable to group D.

Table 1. Changes in pigeon's average weight in different groups during 17 days of the experiment

Group	Mean±SD	p - value
A	290.10 ± 71.74	
B	289.87 ± 71.12	0.0423
C	265.24 ± 37.93	
D	325.04 ± 93.85	

Group A: Herbal mixture treated, Group B: Metronidazole treated, Group C: Control positive group (no treatment), Group D: Control negative group (no disease, no treatment)

3.3. Clinical signs

Fatigue, incapacity to fly, inability to drink and eat with open beaks, an offensive odor, and fluid discharge from the mouth were exhibited by infected birds. Infected pigeons typically exhibited bright yellow substances of varying sizes in their buccal holes. The results of the scoring are shown in Table 2. After seven days of treatment, the appetites of both treated groups returned to normal.

3.4. Biochemical and hematological analysis

One week of post-treatment hematological studies revealed that Hypochromic anemia negatively impacted

Table 2. Score of infection symptoms from zero to four

Group	Before making birds sick	Five days after infection	Seven days after treatment
A	0	3	0
B	0	3	0
C	0	3	4
D	0	0	0

Score zero is normal and healthy pigeons without symptoms of weakness, inability to drink, eat, and fluid discharge from the mouth. Group A: Herbal mixture treated, Group B: Metronidazole treated, Group C: Control positive group (no treatment), Group D: Control negative group (no disease, no treatment)

Table 3. Changes in ALT (IU/l) parameters

Group	Mean±SD	p -value
A	27.45 ± 12.35	1.11e-05
B	27.54 ± 12.24	
C	44.75 ± 29.67	
D	18.04 ± 5.40	

Group A: Herbal mixture treated, Group B: Metronidazole treated, Group C: Control positive group (no treatment), Group D: Control negative group (no disease, no treatment)

the positive control group's squabs with macrocytic and protected groups A and B exhibiting normal blood images. Compared to group D, total serum protein, globulin, and albumin were significantly increased in birds under MTZ and herbal treatment. In addition, ALT, AST, and total cholesterol levels in treated groups were significantly lower than in group D. Infected groups exhibited eosinophilia and basophilia, but after treatment in groups A and B, eosinophil and basophil counts decreased. Tables 3-7 list biochemical and hematological parameters.

Table 4. Changes in total leukocyte count

Group	Mean±SD	p -value
A	15499167 ± 1685882	10.03 8.81e-06
B	15478333 ± 1668818	
C	17340000 ± 3197566	
D	14183333 ± 536118.6	

Group A: Herbal mixture treated, Group B: Metronidazole treated, Group C: Control positive group (no treatment), Group D: Control negative group (no disease, no treatment)

All analyses of data pertaining to weight gain, ALT, and total leukocyte demonstrated the herbal mixture's perfection. Groups A, B, and D gained significantly more weight than group C, but there was no difference between the treated groups ($p > 0.05$, Figure 1). Additionally, ALT levels were significantly lower in groups A, B, and D compared to group C, but there was no difference between treated groups ($p > 0.05$, Figure 2). In addition, total leukocyte counts were significantly lower in groups A, B, and D compared to group C, but there was no difference between treated groups ($p > 0.05$, Figure 3).

Table 5. Hematological Analysis – First Time (Before making birds treatment)

Group	Heterophils (%)	Lymphocytes (%)	Monocytes (%)	Eosinophils (%)	Basophils (%)
A	28.75	60.95	6.33	2.05	1.92
B	28.40	61.07	6.93	1.99	1.61
C	28.04	61.36	6.13	2.28	2.19
D	28.27	61.23	6.43	2.10	1.97

Group A: Herbal mixture treated, Group B: Metronidazole treated, Group C: Control positive group (no treatment), Group D: Control negative group (no disease, no treatment)

Table 6. Hematological Analysis – Second Time (Five days after infection)

Group	Heterophils (%)	Lymphocytes (%)	Monocytes (%)	Eosinophils (%)	Basophils (%)
A	27.17	62.05	5.28	2.83	2.67
B	27.23	61.99	5.08	2.93	2.77
C	27.05	62.13	5.18	2.97	2.67
D	28.27	61.03	6.23	2.20	2.07

Group A: Herbal mixture treated, Group B: Metronidazole treated, Group C: Control positive group (no treatment), Group D: Control negative group (no disease, no treatment)

Table 7. Hematological Analysis – Third Time (Seven days after treatment)

Group	Heterophils (%)	Lymphocytes (%)	Monocytes (%)	Eosinophils (%)	Basophils (%)
A	27.97	61.39	5.98	2.41	2.25
B	28.01	61.09	5.95	2.53	2.42
C	27.02	62.01	5.18	2.99	2.80
D	28.17	61.53	6.03	2.25	2.02

Group A: Herbal mixture treated, Group B: Metronidazole treated, Group C: Control positive group (no treatment), Group D: Control negative group (no disease, no treatment)

4. Discussion

Trichomoniasis is a dangerous infectious disease that causes excessive mortality in pigeon squabs⁴⁴. The current *in-vivo* observation revealed that MTZ application for seven days (50 mg/Kg BW) resulted in complete healing. Analog analysis revealed that MTZ was the protozoal treatment of choice for Columbiformes birds and falcons infected with *T. gallinae*⁴⁵. Metronidazole side effects include toxicity, possible carcinogenic effects, neurological dysfunction, and resistance development despite its primary uses.

Trichomonas gallinae nitroimidazole-resistant isolates were isolated from various parts of the world, including Belgium, Spain, and the USA⁴⁶. *Trichomonas gallinae* drug-resistant isolates will pose a grave threat to birds, especially free-range birds⁴⁷. Consequently, the search for diverse compounds with antitrichomonal properties is essential. *Allium sativum* is a good herb or spice used to provide antimicrobial and antiprotozoal system⁴⁵. The major component of *A. sativum* is diallyl thiosulfinate ($C_3H_5SS(O)C_3H_5$) or allicin, which accounts for 70% of the thiosulfates extracted from

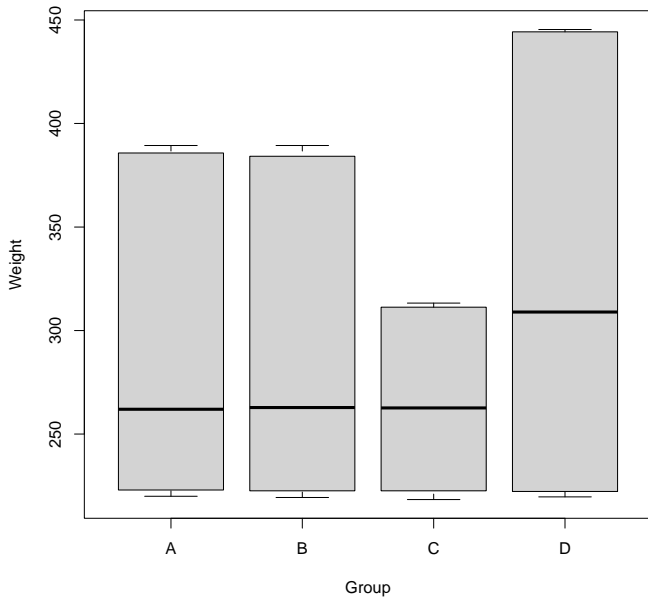


Figure 1. Changes in pigeon's average weight (gr) during 17 days after infection of *Trichomonas gallinae*
Group A: Herbal mixture treated, Group B: Metronidazole treated, Group C: Control positive group (no treatment), Group D: Control negative group (no disease, no treatment)

crushed garlic and is responsible for its aroma and flavor. In addition, it may possess anticancer, antibacterial, antiviral, and antiparasitic effects⁴⁸. Allicin is highly permeable through lipid membranes and is planned to apply its antiproliferative or oxidative damage-inducing properties to the partitions⁴⁹. Antiparasitic activity of Allicin results from its interaction with the thiol groups of various enzymes, such as thioredoxin reductase, alcohol dehydrogenase, and RNA polymerase, which affects the

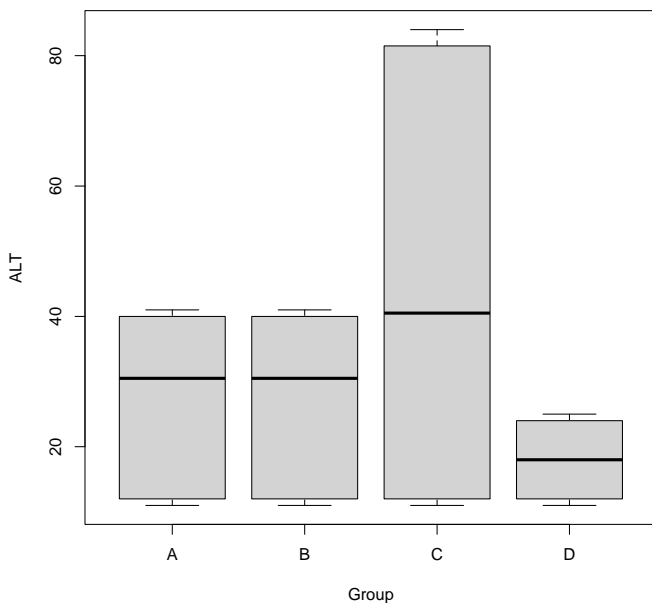


Figure 2. Changes in ALT parameter (IU/l) in infected pigeons with *Trichomonas gallinae*
Group A: Herbal mixture treated, Group B: Metronidazole treated, Group C: Control positive group (no treatment), Group D: Control negative group (no disease, no treatment)

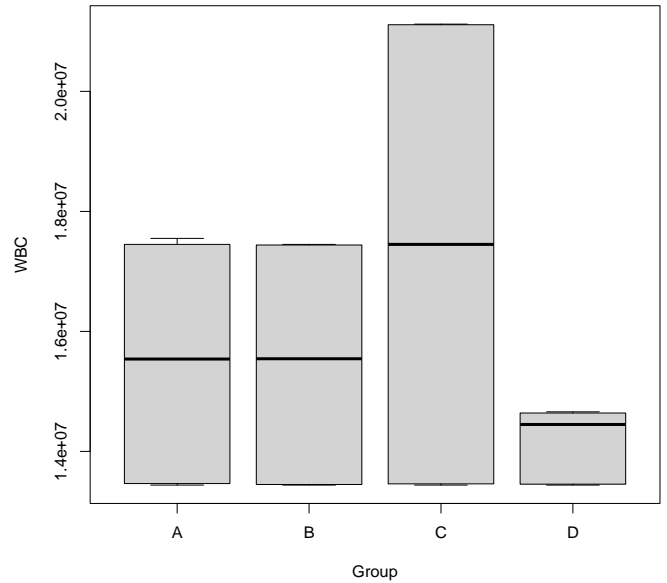


Figure 3. Changes in total leukocyte count ($10^9/L$) in infected pigeons with *Trichomonas gallinae*
Group A: Herbal mixture treated, Group B: Metronidazole treated, Group C: Positive control group (no treatment), Group D: Negative control group (no disease, no treatment)

metabolism of the essential cysteine proteinase and parasite virulence⁵⁰. Additionally, its specific reaction to the free sulfhydryl is contained within the active portion of the cysteine proteinase⁵¹ of the parasite⁵¹. In addition, the organosulfur compound contributes significantly to the medicinal value of *A. sativum*⁵². DTS, Ajoene, and Allyl methyl sulfide are the most responsible active biological substances for the antibacterial, antifungal, antiprotozoal, and antiviral effects of *A. sativum*^{53,54}. Extract of *A. sativum* inhibited the multiplication of *T. gallinae* significantly. An analogue study revealed that *A. sativum* is an effective *in-vitro* treatment for *T. vaginalis*, *T. gallinarum*, and *H. meleagridis*⁵⁵. *Artemisia sativum* demonstrated its efficacy as a phytotherapeutic agent against protozoal infection, and *in-vivo* data revealed a population density of zero. In addition, a 7-day PT (200 mg/Kg) *A. sativum* extract treatment resulted in a complete recovery of the birds. comparable efficacy of *A. sativum* was reported for cryptosporidiosis-infected mice⁵⁶. Treatment with *A. sativum* resulted in greater growth in body weight, compared to the control groups, which were contaminated and treated with MTZ. *Artemisia sativum* also had positive effects on the health condition, development, and performance of piglets⁵⁷. In the herbal-protected group, there was a significant reduction in mortality, and relative efficiency was recorded. *Artemisia sativum* improves the overall performance and health of protected pigeons, which is often interpreted as the substance's effect on mortality. There are reports describing the formulation of *Q. infectoria* powders and the consumption of its extract⁵⁸. Numerous researchers have indicated the anti-biofilm and anti-quorum sensing activity of *Q. infectoria* against a bacterial pathogen⁵⁹. *Quercus infectoria* galls have been found to contain anthocyanins, tannic acid (19.9%), gallic acid (8.75%), amentoflavone hexamethyl ether, syringic

acid, isocryptomerin, starch, methyl-betulate, essential oils, ellagic acid, methyl-oleanate, hexagalloyl-glucose, and polygalloyl-glucose⁶⁰. In addition, *Q. infectoria* extracts have potent antioxidant and free radical scavenging properties. The extract protects proteins and lipids from oxidative damage⁶¹ by chelating the metal ions that catalyze oxidant production. There are 200-400 Asteraceae classifications for *Artemisia* herb species. *Artemisia annua* is the most well-known species with antiparasitic properties, and it grows annually in numerous countries, including Iran, Argentina, Italy, China, the United States, France, and Spain. Essential oils, such as flavonoids, camphene and -camphene, phenolics, amino acids, sesquiterpenoids, vitamins, and minerals, are the primary potential components of *A. annua*⁶². The mechanism of action of the extract involves oxidative stress⁶³. *Artemisia Annua* was utilized in the past to treat fever and malaria³¹. *Artemisia Annua* has also been utilized successfully as an antibacterial, antioxidant, anti-inflammatory, and antihypertensive agent, in addition to its nutritional effects⁶⁴. In addition, this herb can significantly reduce the number of caecal and intestinal *Staphylococcus*, *E. coli*, and *Enterobacteriaceae* colonies while increasing the number of *Lactobacilli*⁶⁵. Incorporating *Artemisia Annua* into a heat-stressed broiler chickens's diet may improve body weight gain, carcass traits, feed utilization, and blood PH. In addition, feeding heat-stressed broiler chickens a diet supplemented with *A. Annua* decreased serum concentrations of MDA, corticosterone, alanine aminotransferase activities (ALT), and aspartate aminotransferase (AST). In comparison to heat-stressed broilers, it increased the levels of tri-iodothyronine (T3), tri-iodothyronine/thyroxine (T3/T4), and serum superoxide dismutase (SOD)⁶⁶. Dietary supplementation with *A. Annua* suggested a potent antiparasitic treatment for coccidiosis in broiler chickens⁶⁷. In addition, *Artemisinin* was found to ameliorate *Eimeria tenella* infections in chickens by decreasing the apoptosis of host cells and halting the inflammatory response by reducing the mRNA expressions of interleukin-17A and NF-B in ceca during infection⁶⁸.

5. Conclusion

A current study indicated that *Q. infectoria*, *Artemisia Annua*, and *Allium Sativum* serve excellent protection in Pigeons against Trichomoniasis.

Declarations

Competing interest

The authors declare no conflict of interest.

Authors' Contribution

Seyed Ali Ghafouri conceptualized, designed, and supervised the study. Abolfazl Ghaniei performed the methodology. Soheil Sadr collected data. Amir Hossein Atazade did the analysis. All authors checked and approved the final version of the manuscript for publication in the present journal.

Availability of Data and Materials

The datasets generated during and analyzed during the current study are available from the corresponding author upon reasonable request.

Funding

This work has not been funded by anybody.

Funding

No funding was received for conducting this study.

Ethical considerations

Ethical issues (including plagiarism, consent to publish, misconduct, data fabrication and/or falsification, double publication and/or submission, and redundancy) have been checked by all the authors.

Acknowledgments

We thank Gholam Reza Razmi and Mehrdad Mohri (Ferdowsi University of Mashhad, Iran) for their support and statements. Also, we want to thank Amir Ali Amiri and Behnoush Dianat (Makian Dam Pars Science-Based Company, Tehran, Iran) for providing us herbal mixture.

References

1. Arfin S, Sayeed M A, Sultana S, Dash A K, and Hossen M L. Prevalence of *Trichomonas gallinae* infection in Pigeon of Jessore District, Bangladesh. *J Adv Vet Anim Res.* 2019 Oct; 6(4):549-552. DOI: [10.5455/javar.2019.f381](https://doi.org/10.5455/javar.2019.f381)
2. Stockdale JE, Dunn JC, Goodman SJ, Morris AJ, Sheehan DK, Grice PV, et al. The protozoan parasite *Trichomonas gallinae* causes adult and nestling mortality in a declining population of European Turtle Doves, *Streptopelia turtur*. *Parasitology*, 2015 Mar; 142(3):490-498. DOI: [10.1017/s0031182014001474](https://doi.org/10.1017/s0031182014001474)
3. Marx M, Reiner G, Willems H, Rocha G, Hillerich K, Masello J F, et al. High prevalence of *Trichomonas gallinae* in wild columbids across western and southern Europe. *Parasit Vectors*, 2017 May; 10(1):242. Available at: <https://parasitesandvectors.biomedcentral.com/articles/10.1186/s13071-017-2170-0>
4. Santos HM, Tsai CY, Catulin GEM, Trangia KCG, Tayo LL, Liu HJ, et al. Common bacterial, viral, and parasitic diseases in pigeons (*Columba livia*): A review of diagnostic and treatment strategies. *Vet Microbiol.* 2020 Aug; 247:108779. DOI: [10.1016/j.vetmic.2020.108779](https://doi.org/10.1016/j.vetmic.2020.108779)
5. Feng SY, Chang H, Li FH, Wang CM, Luo J, and He H X. Prevalence and molecular characterization of *Trichomonas gallinae* from domestic pigeons in Beijing, China. *Infect Genet Evol.* 2018 Nov; 65: 369-372. DOI: [10.1016/j.meegid.2018.08.021](https://doi.org/10.1016/j.meegid.2018.08.021)
6. Lashkenari MS, Nikpay A, Soltani M, and Gerayeli A. *In vitro* antiprotozoal activity of poly (rhodanine)-coated zinc oxide nanoparticles against *Trichomonas gallinae*. *Dispers Sci Technol.* 2019 May; 41(4): 495-502. DOI: [10.1080/01932691.2019.1591972](https://doi.org/10.1080/01932691.2019.1591972)
7. Martínez-Herrero MC, Sansano-Maestre J, Ortega J, González F, López-Márquez I, Gómez-Muñoz MT, et al. Oral trichomoniasis: Description and severity of lesions in birds in Spain. *Vet Parasitol.* 2020 Jul; 283:109196. DOI: [10.1016/j.vetpar.2020.109196](https://doi.org/10.1016/j.vetpar.2020.109196)
8. Quillfeldt P, Schumm YR, Marek C, Mader V, Fischer D, and Marx M. Prevalence and genotyping of *Trichomonas* infections in wild birds in central Germany. *PloS one*, 2018 Aug; 13(8):e0200798. DOI: [10.1371/journal.pone.0200798](https://doi.org/10.1371/journal.pone.0200798)
9. Tabari MA, Poźniak B, Abrishami A, Moradpour AA, Shahavi MH,

- Kazemi S, et al. Antitrichomonal activity of metronidazole-loaded lactoferrin nanoparticles in pigeon trichomoniasis. *Parasitol Res*. 2021 Sep; 120(9):3263-3272. DOI: [10.1007/s00436-021-07263-z](https://doi.org/10.1007/s00436-021-07263-z)
10. Hashemi N, Omidi D, Kheyri P, Khamsepoor F, Setzer WN, and Benchimol M. A review study on the anti-trichomonas activities of medicinal plants. *Int J Parasitol Drugs Drug Resist*. 2021 Apr; 15:92-104. DOI: [10.1016/j.ijpddr.2021.01.002](https://doi.org/10.1016/j.ijpddr.2021.01.002)
 11. Yunessnia lehi A, Shagholani H, Ghorbani M, Nikpay A, Soleimani lashkenarie M, and Soltani M. Chitosan nanocapsule-mounted cellulose nanofibrils as nanoships for smart drug delivery systems and treatment of avian trichomoniasis. *J Taiwan Inst Chem Eng*. 2019 Feb; 95:290-299. DOI: [10.1016/j.jtice.2018.07.014](https://doi.org/10.1016/j.jtice.2018.07.014)
 12. Yuan J, Ni A, Li Y, Bian S, Liu Y, Wang P, et al. Transcriptome Analysis Revealed Potential Mechanisms of Resistance to Trichomoniasis gallinae Infection in Pigeon (*Columba livia*). *Front vet sci*. 2021 Sep; 8:672270. DOI: [10.3389/fvets.2021.672270](https://doi.org/10.3389/fvets.2021.672270)
 13. Youssefi M, Tabari MA, and Moghadamnia A. *In vitro* and *in vivo* activity of Artemisia sieberi against Trichomonas gallinae. *Iran J Vet Res*, 2017 Winter; 18(1):25-29. Available at: <https://pubmed.ncbi.nlm.nih.gov/28588629/>
 14. Nikpay A, and Soltani M. *In vitro* anti-parasitic activities of Pulicaria dysenterica and Lycopus europaeus methanolic extracts against Trichomonas gallinae. *J Herbmed Pharmacol*. 2018; 7(2):112-118. DOI: [10.15171/jhp.2018.19](https://doi.org/10.15171/jhp.2018.19)
 15. Tabari M, Youssefi M, and Moghadamnia A. Antitrichomonal activity of Peganum harmala alkaloid extract against trichomoniasis in pigeon (*Columba livia domestica*). *Br Poult Sci*. 2017 Jun; 58(3):236-241. DOI: [10.1080/00071668.2017.1280725](https://doi.org/10.1080/00071668.2017.1280725)
 16. Tabari MA, and Youssefi MR. *In vitro* and *in vivo* evaluations of Pelargonium roseum essential oil activity against Trichomonas gallinae. *Avicenna J Phytomed*. 2018 Mar; 8(2), 136-142. Available at: <https://pubmed.ncbi.nlm.nih.gov/29632844/>
 17. Ji F, Zhang D, Shao Y, Yu X, Liu X, Shan D, et al. Changes in the diversity and composition of gut microbiota in pigeon squabs infected with Trichomonas gallinae. *Sci Rep*, 2020 Nov; 10:19978. Available at: <https://www.nature.com/articles/s41598-020-76821-9>
 18. Farinacci P, Mevissen M, Ayrle H, Maurer V, Dalgaard TS, Melzig MF, et al. Medicinal plants for prophylaxis and therapy of common infectious diseases in poultry—a systematic review of *in vivo* studies. *Planta Med*. 2021 Mar;88(3-4):200-217. DOI: [10.1055/a-1543-5502](https://doi.org/10.1055/a-1543-5502)
 19. Malekifard F, Tavassoli M, and Alimoradi M. *In vitro* assessment of anti-Trichomonas effects of Zingiber officinale and Lavandula angustifolia alcoholic extracts on Trichomonas gallinae. *Vet Res Forum*. 2021 Winter; 12(1):95-100. DOI: [10.30466/vrf.2019.102620.2444](https://doi.org/10.30466/vrf.2019.102620.2444)
 20. Rezaee H, Ghorbani M, Nikpay A, and Soltani M. Tannic acid-coated zeolite Y nanoparticles as novel drug nanocarrier with controlled release behavior and anti-protozoan activity against Trichomonas gallinae. *Dispers Sci Technol*. 2018 Oct; 40(4):587-593. DOI: [10.1080/01932691.2018.1475240](https://doi.org/10.1080/01932691.2018.1475240)
 21. Ardestani MM, Aliahmadi A, Toliati T, Dalimi A, Momeni Z, and Rahimi R. Antimicrobial activity of Quercus infectoria gall and its active constituent, gallic acid, against vaginal pathogens. *Tradit Integrat Med*. 2019 Winter; 4(1):12-21. DOI: [10.18502/tim.v4i1.1664](https://doi.org/10.18502/tim.v4i1.1664)
 22. Elham A, Arken M, Kalimanjan G, Arkin A, and Iminjan M. A review of the phytochemical, pharmacological, pharmacokinetic, and toxicological evaluation of Quercus infectoria galls. *J Ethnopharmacol*. 2021 Jun; 273:113592. DOI: [10.1016/j.jep.2020.113592](https://doi.org/10.1016/j.jep.2020.113592)
 23. Tonda R, Rubach J, Lumpkins B, Mathis G, and Poss M. Effects of tannic acid extract on performance and intestinal health of broiler chickens following coccidiosis vaccination and/or a mixed-species Eimeria challenge. *Poult Sci*. 2018 Sep; 97(9):3031-3042. DOI: [10.3382/ps/pey158](https://doi.org/10.3382/ps/pey158)
 24. Burlacu E, Nisca A, and Tanase C. A comprehensive review of phytochemistry and biological activities of Quercus species. *Forests*. 2020 Aug; 11(9):904. DOI: [10.3390/f11090904](https://doi.org/10.3390/f11090904)
 25. Huang Q, Liu X, Zhao G, Hu T, and Wang Y. Potential and challenges of tannins as an alternative to in-feed antibiotics for farm animal production. *Anim Nutr*. 2018 Jun; 4(2):137-150. DOI: [10.1016/j.aninu.2017.09.004](https://doi.org/10.1016/j.aninu.2017.09.004)
 26. Jamil M, Aleem M T, Shaikat A, Khan A, Mohsin M, Rehman T U, et al. Medicinal Plants as an Alternative to Control Poultry Parasitic Diseases. *Life*. 2022 Mar ; 12(3):449. DOI: [10.3390/life12030449](https://doi.org/10.3390/life12030449)
 27. Srinivasulu C, Ramgopal M, Ramanjaneyulu G, Anuradha C, and Kumar CS. Syringic acid (SA)—a review of its occurrence, biosynthesis, pharmacological and industrial importance. *Biomedicine & Pharmacotherapy*, 2018 Dec; 108:547-557. DOI: [10.1016/j.biopha.2018.09.069](https://doi.org/10.1016/j.biopha.2018.09.069)
 28. Tayel AA, El-Sedfy MA, Ibrahim AI, and Moussa SH. Application of Quercus infectoria extract as a natural antimicrobial agent for chicken egg decontamination. *Rev Argent Microbiol*. 2018 Oct-Dec; 50(4):391-397. DOI: [10.1016/j.ram.2017.12.003](https://doi.org/10.1016/j.ram.2017.12.003)
 29. van der Kooy F, and Sullivan SE. The complexity of medicinal plants: the traditional Artemisia annua formulation, current status and future perspectives. *J Ethnopharmacol*. 2013 Oct; 150(1):1-13. DOI: [10.1016/j.jep.2013.08.021](https://doi.org/10.1016/j.jep.2013.08.021)
 30. Shahrajabian MH, Wenli S, and Cheng Q. Exploring Artemisia annua L., artemisinin and its derivatives, from traditional Chinese wonder medicinal science. *Not Bot Horti Agrobot*. 2020 Dec; 48(4):1719-1741. DOI: [10.15835/nbha48412002](https://doi.org/10.15835/nbha48412002)
 31. Feng X, Cao S, Qiu F, and Zhang B. Traditional application and modern pharmacological research of Artemisia annua L. *Pharmacol Ther*. 2020 Dec ; 216:107650. DOI: [10.1016/j.pharmthera.2020.107650](https://doi.org/10.1016/j.pharmthera.2020.107650)
 32. Kim JT, Park JY, Seo HS, Oh HG, Noh JW, Kim JH, Kim DY, and Youn HJ. *In vitro* antiprotozoal effects of artemisinin on Neospora caninum. *Vet Parasitol*. 2002 Jan; 103(1-2):53-63. DOI: [1016/s0304-4017\(01\)00580-5](https://doi.org/10.1016/s0304-4017(01)00580-5)
 33. Müller J, Balmer V, Winzer P, Rahman M, Manser V, Haynes RK, et al. *In vitro* effects of new artemisinin derivatives in Neospora caninum-infected human fibroblasts. *Int J Antimicrob Agents*. 2015 Jul; 46(1):88-93. DOI: [10.1016/j.ijantimicag.2015.02.020](https://doi.org/10.1016/j.ijantimicag.2015.02.020)
 34. Nagai A, Yokoyama N, Matsuo T, Bork S, Hirata H, Xuan X, et al. Growth-inhibitory effects of artesunate, pyrimethamine, and pamaquine against Babesia equi and Babesia caballi in *in vitro* cultures. *Antimicrob Agents Chemother*. 2003 Feb; 47(2):800-803. DOI: [10.1128/aac.47.2.800-803.2003](https://doi.org/10.1128/aac.47.2.800-803.2003)
 35. Chadwick M, Trewin H, Gawthrop F, and Wagstaff C. Sesquiterpenoids lactones: benefits to plants and people. *Int J Mol Sci*. 2013 Jun; 14(6):12780-12805. DOI: [10.3390/ijms140612780](https://doi.org/10.3390/ijms140612780)
 36. Ferreira JF, Luthria DL, Sasaki T, and Heyerick A. Flavonoids from Artemisia annua L. as antioxidants and their potential synergism with artemisinin against malaria and cancer. *Molecules*. 2010 Apr; 15(5):3135-3170. DOI: [10.3390/molecules15053135](https://doi.org/10.3390/molecules15053135)
 37. Yuan H, Ma Q, Cui H, Liu G, Zhao X, Li W, et al. How can synergism of traditional medicines benefit from network pharmacology? *Molecules*. 2017 Jul; 22(7):1135. DOI: [10.3390/molecules22071135](https://doi.org/10.3390/molecules22071135)
 38. Nigam M, Atanassova M, Mishra A P, Pezzani R, Devkota H P, Plygun S, et al. Bioactive compounds and health benefits of Artemisia species. *Nat Prod Commun*. 2019 Jul; 14(7):1-7. DOI: [10.1177/1934578X19850354](https://doi.org/10.1177/1934578X19850354)
 39. Alloui MN, Agabou A, and Alloui N. Application of herbs and phytochemical feed additives in poultry production-A Review. *Glob J Anim Sci*. 2014 Jun; 2(3):234-243. Available at: <http://archives.gjasr.com/index.php/GJASR/article/download/57/155>
 40. Brzóška F, Sliwinski B, Michalik-Rutkowska O, and Sliwa J. The effect of garlic (*Allium sativum* L.) on growth performance, mortality rate, meat and blood parameters in broilers. *Ann Anim Sci*. 2015 Jul; 15(4):961-975. DOI: [10.1515/aaoas-2015-0052](https://doi.org/10.1515/aaoas-2015-0052)
 41. Sunu P, Sunarti D, Mahfudz LD, and Yunianto VD. Effect of synbiotic from *Allium sativum* and *Lactobacillus acidophilus* on hematological indices, antioxidative status and intestinal ecology of broiler chicken. *J Saudi Soc Agric Sci*. 2021 Feb; 20(2):103-110. DOI: [10.1016/j.jssas.2020.12.005](https://doi.org/10.1016/j.jssas.2020.12.005)
 42. Espinoza T, Valencia E, Albarrán M, Díaz D, Quevedo RA, Díaz O, et al. Garlic (*Allium sativum* L.) and Its beneficial properties for health: A review. *Agroind sci*. 2020; 10(1):103-115. DOI: [10.17268/agroindsci.2020.01.14](https://doi.org/10.17268/agroindsci.2020.01.14)
 43. Ezeorba TPC, Chukwudozie KI, Ezema CA, Anaduaka EG, Nweze EJ, and Okeke ES Potentials for health and therapeutic benefits of garlic essential oils: Recent findings and future prospects. *Pharmacol Res-Modern Chinese Med*, 2022 Jun; 3:100075. DOI: [10.1016/j.prmcm.2022.100075](https://doi.org/10.1016/j.prmcm.2022.100075)
 44. Ganas P, Jaskulska B, Lawson B, Zdravec M, Hess M, and Bilic I. Multi-locus sequence typing confirms the clonality of Trichomonas gallinae isolates circulating in European finches. *Parasitology*. 2014 Apr; 141(5): 652-661. DOI: [10.1017/s0031182013002023](https://doi.org/10.1017/s0031182013002023)
 45. Seddiek SA, El-Shorbagy MM, Khater HF, and Ali AM. The antitrichomonal efficacy of garlic and metronidazole against

- Trichomonas gallinae infecting domestic pigeons. Parasitol Res, 2014 Apr; 113(4):1319-1329. DOI: [10.1007/s00436-014-3771-6](https://doi.org/10.1007/s00436-014-3771-6)
46. Baccega B, Alves MSD, Neves RN, Velho MC, de Godoi SN, Ourique AF, et al. Free essential oils and nanostructured on Trichomonas gallinae trophozoites. Disciplinary Scientia | Naturais e Tecnológicas, 2019; 20(3):337-354.
 47. Rouffaer L, Adriaensen C, De Boeck C, Claerebout E, and Martel A. Racing pigeons: a reservoir for nitro-imidazole-resistant Trichomonas gallinae. J Parasitol. 2014 Jun; 100(3): 360-363. DOI: [10.1645/13-359.1](https://doi.org/10.1645/13-359.1)
 48. El-Saber Batiha G, Magdy Beshbishy AG, Wasef L, Elewa YHA, Al-Sagan A, Abd El-Hack ME, et al. Chemical constituents and pharmacological activities of garlic (Allium sativum L.): A review. Nutrients, 2020 Mar; 12(3):872. DOI: [10.3390/nu12030872](https://doi.org/10.3390/nu12030872)
 49. Chan JYY, Yuen ACY, Chan RYK, and Chan SW. A review of the cardiovascular benefits and antioxidant properties of alliin. Phytother Res. 2013 May; 27(5):637-646. DOI: [10.1002/ptr.4796](https://doi.org/10.1002/ptr.4796)
 50. Miron T, Rabinkov A, Mirelman D, Wilchek M, and Weiner L. The mode of action of alliin: its ready permeability through phospholipid membranes may contribute to its biological activity. Biochim Biophys Acta. 2000 Jan; 1463(1):20-30. DOI: [10.1016/s0005-2736\(99\)00174-1](https://doi.org/10.1016/s0005-2736(99)00174-1)
 51. Coppi A, Cabinian M, Mirelman D, and Sinnis P. Antimalarial activity of alliin, a biologically active compound from garlic cloves. Antimicrob Agents Chemother, 2006 May; 50(5):1731-1737. DOI: [10.1128/aac.50.5.1731-1737.2006](https://doi.org/10.1128/aac.50.5.1731-1737.2006)
 52. Rouf R, Uddin SJ, Sarker DK, Islam MT, Ali ES, Shilpi JA, et al. Antiviral potential of garlic (Allium sativum) and its organosulfur compounds: A systematic update of pre-clinical and clinical data. Trends Food Sci Technol. 2020 Oct; 104: 219-234. DOI: [10.1016/j.tifs.2020.08.006](https://doi.org/10.1016/j.tifs.2020.08.006)
 53. Ashfaq F, Ali Q, Haider M, Hafeez M, and Malik A. Therapeutic activities of garlic constituent phytochemicals. Biol Clin Sci Res J. 2021 Feb; 2021:53. Available at: <https://bcsrj.com/ojs/index.php/bcsrj/article/view/53>
 54. Kovarovič J, Bystricka J, Vollmannova A, Toth T, and Brindza J. Biologically valuable substances in garlic (Allium sativum L.)—A review. J Cent Eur Agric. 2019 ; 20(1):292-304. DOI: [10.5513/JCEA01/20.1.2304](https://doi.org/10.5513/JCEA01/20.1.2304)
 55. Zenner L, Callait M, Granier C, and Chauve C. *In vitro* effect of essential oils from Cinnamomum aromaticum, Citrus limon and Allium sativum on two intestinal flagellates of poultry, Tetratrichomonas gallinarum and Histomonas meleagridis. Parasite. 2003 Jun; 10(2):153-157. DOI: [10.1051/parasite/2003102153](https://doi.org/10.1051/parasite/2003102153)
 56. Gaafar MR. Efficacy of Allium sativum (garlic) against experimental cryptosporidiosis. Alexandria J Med. 2019 May; 48(1):59-66. DOI: [10.1016/j.ajme.2011.12.003](https://doi.org/10.1016/j.ajme.2011.12.003)
 57. Ayrle H, Mevissen M, Kaske M, Nathues H, Gruetzner N, Melzig M, et al. Medicinal plants—prophylactic and therapeutic options for gastrointestinal and respiratory diseases in calves and piglets? A systematic review. BMC Vet Res, 2016 Jun; 12:89. DOI: [10.1186/s12917-016-0714-8](https://doi.org/10.1186/s12917-016-0714-8)
 58. Kamarudin NA, Muhamad N, Salleh NN, Tan SC. Impact of Solvent Selection on Phytochemical Content, Recovery of Tannin and Antioxidant Activity of Quercus Infectoria Galls. Pharmacognosy J. 2021; 13(5): 1195-1204. DOI: 10.5530/pj.2021.13.153
 59. WA WNA, Masrah M, Hasmah A, and NJ N I. *In vitro* antibacterial activity of Quercus infectoria gall extracts against multidrug resistant bacteria. Trop Biomed, 2014 Dec; 31(4):680-688. Available at: <https://pubmed.ncbi.nlm.nih.gov/25776593/>
 60. Fan SH, Ali NA, and Basri DF. Evaluation of analgesic activity of the methanol extract from the galls of Quercus infectoria (Olivier) in rats. Evid Based Complement Alternat Med. 2014 Aug; 2014:976764. DOI: [10.1155/2014/976764](https://doi.org/10.1155/2014/976764)
 61. Baharuddin NS, Abdullah H, and Wahab WNAWA. Anti-Candida activity of Quercus infectoria gall extracts against Candida species. J Pharm Bioallied Sci. 2015 Jan-Mar; 7(1):15-20. DOI: [10.4103/0975-7406.148742](https://doi.org/10.4103/0975-7406.148742)
 62. Septembre-Malaterre A, Lalarizo Rakoto M, Marodon C, Bedoui Y, Nakab J, Simon E, et al. Artemisia annua, a traditional plant brought to light. Int J Mol Sci. 2020 Jul; 21(14): 4986. DOI: [10.3390/ijms21144986](https://doi.org/10.3390/ijms21144986)
 63. Guo S, Ma J, Xing Y, Xu Y, Jin X, Yan S, et al. Artemisia annua L. aqueous extract as an alternative to antibiotics improving growth performance and antioxidant function in broilers. Front Vet Sci. 2020 Jul; 9:934021. DOI: [10.3389/fvets.2022.934021](https://doi.org/10.3389/fvets.2022.934021)
 64. Koul B, Taak P, Kumar A, Khatri T, and Sanyal I. The Artemisia genus: A review on traditional uses, phytochemical constituents, pharmacological properties and germplasm conservation. J Glycom Lipidom. 2017; 7(1):100042. DOI: [10.4172/2153-0637.1000142](https://doi.org/10.4172/2153-0637.1000142)
 65. Bilia AR, Santomauro F, Sacco C, Bergonzi MC, and Donato R. Essential oil of Artemisia annua L.: an extraordinary component with numerous antimicrobial properties. Evid Based Complement Alternat Med. 2014 Apr; 2014:159819. DOI: [10.1155/2014/159819](https://doi.org/10.1155/2014/159819)
 66. Song Z, Cheng K, Zheng X, Ahmad H, Zhang L, and Wang T. Effects of dietary supplementation with enzymatically treated Artemisia annua on growth performance, intestinal morphology, digestive enzyme activities, immunity, and antioxidant capacity of heat-stressed broilers. Poult Sci, 2018 Feb; 97(2):430-437. DOI: [10.3382/ps/pex312](https://doi.org/10.3382/ps/pex312)
 67. Habibi H, Firouzi S, Nili H, Razavi M, Asadi S L, and Daneshi S. Anticoccidial effects of herbal extracts on Eimeria tenella infection in broiler chickens: *In vitro* and *in vivo* study. J Parasit Dis. 2016 Jun; 40(2):401-407. DOI: [10.1007/s12639-014-0517-4](https://doi.org/10.1007/s12639-014-0517-4)
 68. Jiao J, Yang Y, Liu M, Li J, Cui Y, Yin S, et al. Artemisinin and Artemisia annua leaves alleviate Eimeria tenella infection by facilitating apoptosis of host cells and suppressing inflammatory response. Vet Parasitol. 2018 Apr; 254:172-177. DOI: [10.1016/j.vetpar.2018.03.017](https://doi.org/10.1016/j.vetpar.2018.03.017)